

Aortoenteric Fistula-A Bomb in the Emergency Department: Suspect and do not Wait

Şerife Özdiñç¹, Sezgin Yılmaz², Neşe Nur User¹

¹Department of Emergency Medicine, Afyon Kocatepe University Faculty of Medicine, Afyonkarahisar, Turkey

²Department of General Surgery, Afyon Kocatepe University Faculty of Medicine, Afyonkarahisar, Turkey

Abstract

Aortoenteric fistulas (AEF) are uncommon but fatal complications during aortic surgery that can cause heavy gastrointestinal bleeding (GIB). We present a patient who underwent aortic surgery and developed GIB that led to hemorrhagic shock. A 66-year-old man was transferred to our emergency department (ED) because of deterioration in his general condition. On arrival at the ED, he was confused, pale, cooperative, cold, and sweaty. His blood pressure was 70/40 mmHg and pulse rate, 130/min. Plenty of fresh blood was seen in the nasogastric tube. We learned from patient's family that he had undergone aortic surgery. The surgical team was notified regarding the possibility of an AEF. The patient was transferred to the operating room immediately without any imaging tests being performed. In patients with massive GIB who had undergone aortic surgery, AEF should be considered. When considering the diagnosis of AEF, surgical intervention should be performed as soon as possible before performing diagnostic tests. (*Eurasian J Emerg Med* 2015; 14: 145-7)

Keywords: Aortic surgery, aortoenteric fistula, gastrointestinal bleeding

Introduction

Patients with gastrointestinal bleeding (GIB) are frequently encountered in the emergency department (ED). There are many causes of GIB, and one of the most dangerous cause is an aortoenteric fistula (AEF). AEFs are divided into two groups (1): primary fistulas occur in patients with no past history of aortic surgery; secondary fistulas occur in 0.4%–1.6% of cases and a comparatively uncommon but deadly complication of aortic surgery (2). AEFs are more common in men in the sixth decade of life (1). They usually present 8–18 months after the original aortic surgery (3). The patient complains of abdominal or back pain, fever, nausea, vomiting, and symptoms of GIB (4). A delay in identification of the fistula can give rise to fatal bleeding. We present a patient who had undergone aortic surgery and developed the signs of GIB, leading to hemorrhagic shock. The purpose of this case report is to alert clinicians about history of aortic surgery as a risk factor for AEF, causing GIB. In addition, this case stresses the significance of consulting a surgeon without delay when suspecting AEF in a patient admitted to the ED with GIB.

Case Presentation

A 66-year-old man was transferred to our emergency department because of deterioration in his general condition. He was previously admitted at another hospital because of hematemesis. On arrival at the ED, he was confused, cooperative, pale, cold, and sweaty. On examination, his blood pressure was 70/40 mmHg, and radial pulse rate was 130 beats/min, palpable, and weak. There was a vascular access, nasogastric tube, and urinary catheter. There was plenty of bleeding from the nasogastric tube and no urine was being drained from the urinary catheter. An abdominal vertical incision scar that began under the xiphoid and extended below the navel was observed. His abdomen was soft and tender. The patient was monitored. Nasal oxygen was administered, intravenous fluid and red blood cell transfusion was initiated, and proton pump inhibitor [pantoprazole, 80 mg intravenous (IV) bolus and 8 mg/h IV infusion] was given. We learned from patient's family that approximately one and a half months ago, he had undergone aortic surgery for abdominal aortic aneurysm. Imaging studies such as abdominal computed tomography could not be performed as the patient was unstable. The surgical team was immediately notified

Correspondence to: Şerife Özdiñç e-mail: drseri03@hotmail.com

Received: 25.12.2014 **Accepted:** 13.01.2015 **Available Online Date:** 12.06.2015

©Copyright 2015 by Emergency Physicians Association of Turkey - Available online at www.eajem.com

DOI: 10.5152/jaem.2015.98216



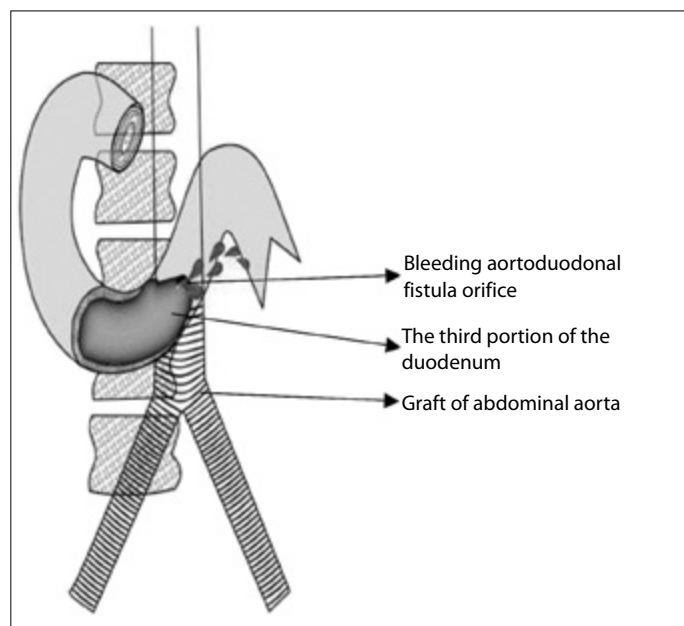


Figure 1. Bleeding aortoduodenal fistula orifice in the third portion of the duodenum (This figure was designed and drawn by instructor Fügen Gönül)

regarding the possibility of AEF. The patient was immediately transported to the operating room. The patient underwent laparotomy under general anesthesia. Gastrotomy, pylorotomy, and duodenotomy were performed; however, the bleeding site could not be identified. A bleeding aortoduodenal fistula orifice was seen at the distal end of the third part of the duodenum (Figure 1). The aorta was repaired, bleeding was stopped, and the distal duodenum was closed. A drain was placed in the proximal duodenum. Tube duodenotomy and gastrojejunostomy braun anastomosis were performed. Feeding jejunostomy was placed. Intubated patient was admitted to the intensive care unit. Unfortunately, the patient survived only for two days before death by multiorgan failure.

Discussion

Aortic surgery is an effective technique for the treatment of abdominal aortic aneurysm. AEF is a rare complication of this surgery, occurring in 0.4%–1.6% of cases (2). An AEF can be found between the aorta and any part of the intestine, however, it is observed in almost 55%–60% in third portion of the duodenum (1). The mechanism of fistula formation is yet to be elucidated. The most commonly accepted mechanism is aortic wall erosion by a stent graft (5). AEF occurs from 8 to 180 months after aneurysm repair (3). In the present case, it occurred very early.

The classic triad of AEF is pain, pulsatile mass, and GIB, although these are unusual findings (1). Symptoms are often ambiguous or nonspecific. Fever of unknown origin or sepsis may be the only presenting mark of AEF (6). In the present case, it presented as massive GIB. Knowing the patient's history is important to a diagnosis of AEF. However, patients and their family may not know their surgical histories, and the diagnosis of AEF is generally not taken into account. In this case, we learned from the patient's family that he had undergone aortic surgery for abdominal aortic aneurysm; hence, we suspected AEF and immediately notified the surgical team regarding the pos-

sibility of AEF. The patient was sent to the operating room without endoscopy or computed tomography (CT) scan being performed. Approximately 5% of patients with AEF present with massive GIB (1). In the beginning, several mechanisms of the body try to compensate for GIB within hours or days before massive GIB develops (7). If a suspicion of AEF comes to mind during this time, the patient's chances of survival can increase. A delay of over 24 hours in diagnosis and surgical treatment increases mortality (1). Unless the AEF is repaired, the mortality rate is 100% (8). Mortality rates have been reported to range from 40% to 85%, even in cases where AEF is diagnosed promptly and treated immediately (6). Perioperative mortality is 21% in patients with shock (9). Although AEF in our case was diagnosed and operated in less than 5 hours, the patient died on the second day after the surgery, not from the bleeding but as a result of multiorgan failure.

Computed tomography affirms diagnosis of AEF in 33%–80% of cases (10). Endoscopy is an alternate diagnostic method of AEF; however, it does not definitively rule out the diagnosis of fistula. In addition, incorrect and misleading sources of bleeding, such as a coincidental gastritis, duodenitis, or peptic ulcer, can be detected (1) and AEF may be excluded. Besides, an endoscope cannot reach the distal part of the duodenum. Arteriography, angiography, magnetic resonance imaging, and scintigraphy are also useful in the diagnosis of AEF; however, none of these diagnostic tests can be performed in unstable patients. Diagnosis in most of the cases is made by surgical exploration. In the present case, the patient was admitted with GIB, and hemorrhagic shock symptoms were seen. The patient's vital signs were not stable; hence, neither CT nor endoscopy could be performed for confirming the diagnosis. He was transferred to the operating room without delay. Hence, diagnosis of AEF was made by surgical exploration. As a result, this case shows the significance of considering a diagnosis of AEF when a patient is admitted to the ED with abundant bleeding and consulting a surgeon before imaging studies are performed. This increases the patient's chances of survival.

Conclusion

Aortoenteric fistula is a rare but an important cause of fatal gastrointestinal bleeding. It should be considered in patients with massive gastrointestinal bleeding who have undergone aortic surgery. When considering this diagnosis, surgical intervention should be done as soon as possible, before diagnostic tests were performed.

Informed Consent: Written informed consent was obtained from patients' parents who participated in this case.

Peer-review: Externally peer-reviewed.

Acknowledgements: We thank Instructor Fügen Gönül (Faculty of Fine Arts, Department of Communication Design and Graphics, Afyon Kocatepe University) for design and drawing of figure.

Conflict of Interest: No conflict of interest was declared by the authors.

Financial Disclosure: The authors declared that this study has received no financial support.

References

1. Ramsay AC, Ramsay MP, Meekins PE. Aortoenteric fistula in a 25-year-old man. *J Emerg Med* 2013; 45: 533-6. [CrossRef]

2. Busuttil SJ, Goldstone J. Diagnosis and management of aortoenteric fistulas. *Semin Vasc Surg* 2001; 14: 302-11. [\[CrossRef\]](#)
3. Luo CY, Lai CH, Wen JS, Lin BW. Secondary aortocolic fistula: case report and review of the literature. *Ann Vasc Surg* 2010; 24: 256.e5-12. [\[CrossRef\]](#)
4. Chenu C, Marcheix B, Barcelo C, Rousseau H. Aorto-enteric fistula after endovascular abdominal aortic aneurysm repair: case report and review. *Eur J Vasc Endovasc Surg* 2009; 37: 401-6. [\[CrossRef\]](#)
5. Bertges DJ, Vilella ER, Makaroun MS. Aortoenteric fistula due to endoleak coil embolization after endovascular AAA repair. *J Endovasc Ther* 2003; 10: 130-5. [\[CrossRef\]](#)
6. Florendo FT, Harmon HC. Aortoenteric fistula: a mandatory early operative diagnosis. *South Med J* 1979; 72: 1516-8. [\[CrossRef\]](#)
7. Champion MC, Sullivan SN, Coles JC, Goldbach M, Watson WC. Aortoenteric fistula: incidence, presentation, recognition, and management. *Ann Surg* 1982; 195: 314-7. [\[CrossRef\]](#)
8. Doney MK, Vilke GM. Case report: aortoenteric fistula presenting as repeated hematochezia. *J Emerg Med* 2012; 43: 431-4. [\[CrossRef\]](#)
9. Armstrong PA, Back MR, Wilson JS, Shames ML, Johnson BL, Bandyk DF. Improved outcomes in the recent management of secondary aortoenteric fistula. *J Vasc Surg* 2005; 42: 660-6. [\[CrossRef\]](#)
10. Ruby BJ, Cogbill TH. Aortoduodenal fistula 5 years after endovascular abdominal aortic aneurysm repair with the Ancure stent graft. *J Vasc Surg* 2007; 45: 834-6. [\[CrossRef\]](#)