

Foreign in Colon

Yasemin Kayadibi¹, Deniz Çebi Olgun¹, Evrim Özmen¹, Rahşan Özcan², Afşin İpekçi³, İbrahim İkizceli³

¹Department of Radiology, İstanbul University Cerrahpaşa Faculty of Medicine, İstanbul, Turkey

²Department of Pediatric Surgery, İstanbul University Cerrahpaşa Faculty of Medicine, İstanbul, Turkey

³Department of Emergency Medicine, İstanbul University Cerrahpaşa Faculty of Medicine, İstanbul, Turkey

Abstract

An amulet with a blue bead and metal coin are the most common causes of foreign body ingestion in childhood in Turkey. There are few case reports of metal spoons ingested in the literature. In this case report, our aim is to report a teaspoon that was found incidentally in the ascending colon as an uncommon cause of foreign body ingestion. (*JAEM 2014; 13: 204-5*)

Key words: Gastrointestinal tract, metallic spoon, foreign body ingestion

Introduction

Foreign body ingestion is a problem often encountered in childhood, and the majority of children who swallow foreign bodies is under the age of 4. Although coins and amulets are the most commonly ingested foreign bodies in this age group in our country, toy pieces, pins, and disc-shaped batteries are other forms of commonly ingested foreign bodies (1, 2). In the literature, there are only a few cases of ingested spoons (3). In this case report, our aim is to present the radiological findings of an incidentally found metallic spoon in the ascending colon of a 13-year-old patient.

Case Presentation

A 13-year-old male patient was admitted to the emergency department with abdominal pain. There was no pathological finding on physical examination, and his complete blood count was within normal limits, but there was microscopic hematuria in his urinalysis. For future evaluation, the patient was directed to our radiology department. On the standing direct abdominal radiograph, a vertical teaspoon was viewed that was fixed in the right lower quadrant (Fig. 1). There was no sub diaphragmatic free air image that suggested perforation. The foreign body could not be seen on abdominal sonography, so computer tomography (CT) was performed. The CT of the abdomen showed a vertical localized metallic foreign image and artifacts in the junction of the ascending colon and cecum (Figs 2 a and b). The patient was managed conservatively, and serial radiographs were taken until the transition of the spoon was viewed

through the colon (Figs. 3 a and b). Exit of the metal spoon by defecation was confirmed in the outpatient follow-up.

Discussion

Approximately 80% of patients who are admitted to the emergency department with complaints of foreign body ingestion are in the pediatric age group. The vast majority of these pediatric patients is under the age of 4. Amulets are the most frequently ingested objects due to its common usage in our country. Other forms of detected foreign bodies are toy pieces, safety pins, and disc-shaped batteries in childhood; pins in the adolescent group; and toothpicks, bone fragments, bones, and dental prostheses in the adult group (1, 2, 4, 5). In the literature, a few cases have been reported of ingested spoons (3). A patient's psychiatric conditions, such as suicide, depression, bipolar disorder, schizophrenia, and masochism, could be possible underlying problems in the adult group. In our case, the patient and his family did not give any information and denied ingestion. We considered that the patient had probably ingested the spoon in his early childhood and did not remember or that he and his family intentionally denied, or maybe the patient had underlying psychiatric problems.

In childhood, patients are generally asymptomatic otherwise their family history. Stomach pain, dysphagia, vomiting, abnormal secretion, and retrosternal pain are the most common symptoms in symptomatic cases (1, 2, 4, 5).

There are three anatomic narrows in the esophagus: upper and lower esophageal sphincter and aortic cross. In 90% of cases, passage



Correspondence to: Deniz Çebi Olgun; Department of Radiology, İstanbul University Cerrahpaşa Faculty of Medicine, İstanbul, Turkey
Phone: +90 536 257 08 79 e-mail: denizcebiolgun@gmail.com

Received: 08.03.2014 **Accepted:** 23.04.2014

©Copyright 2014 by Emergency Physicians Association of Turkey - Available online at www.akademikaciltip.com
DOI: 10.5152/jaem.2014.174

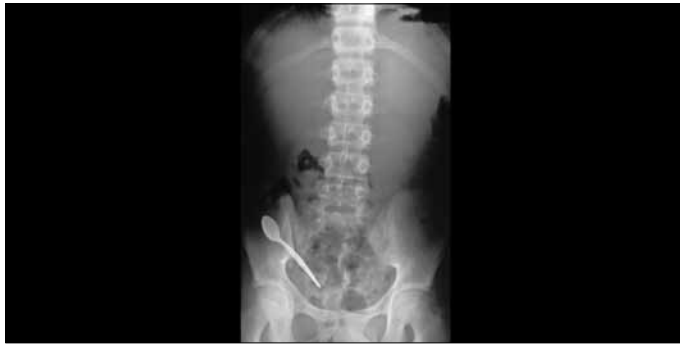

Figure 1. Standing direct abdominal radiograph shows a vertical teaspoon fixed in the right lower quadrant

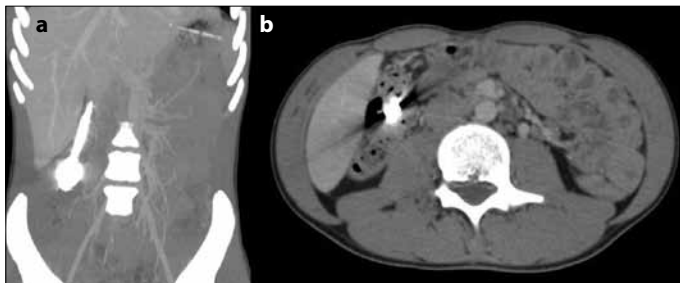


Figure 2. a, b. Coronal CT maximum intensity projection (MIP) and axial MIP images show vertical localized metallic foreign image and artifacts in the junction of the ascending colon and cecum

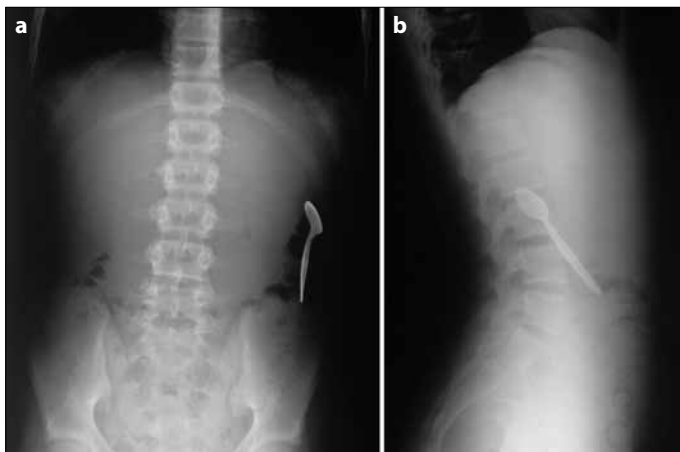


Figure 3. a, b. Control standing direct abdominal radiograph shows teaspoon in the left colon localization

occurs spontaneously from the esophagus. Objects that are greater than 2 cm in diameter and 6 cm long can be attached to the pylorus or duodenum. Ileocecal valve, like in our patient, is another localization that the object may be attached to during gastrointestinal passage (1, 2, 4-6). In the literature, there are reported cases that had attached to the lumen of Meckel's diverticulum or the appendix and led to inflammation (1, 7). Swallowed foreign bodies are likely to pass the gastrointestinal tract spontaneously, as in our patient. In 10% of patients, endoscopic management is required, and in 1% of cases, surgical intervention is required (1, 2, 4-6).

Radiologic imaging takes an important role in determining the location. Plain X-ray graphs are the first preferred imaging modality, with its advantages, like being cost-effective and easy accessibility. If the ingested object is radio-opaque, plain graphies could give information

about the presence and localization. Additionally, the determination of free air could be detected easily by plain graphies if perforation has occurred. CT is usually preferred if the object is non-radio-opaque, to exclude complications, or to see the relationship with surrounding tissues. Complications depend on the dimensions and shape of the object that was swallowed. Swallowed pointed objects, such as safety pins, fish bones, and needles, may cause retropharyngeal abscess, carotid artery rupture, hemorrhage, esophageal perforation, mediastinitis, aorto-esophageal fistula, and pneumothorax, and chemicals, such as batteries, may cause mucosal erosion and perforation (1, 2, 4-6). If the foreign bodies are radio-opaque and there is no sign of complications, patients can be managed conservatively by following up the passage with plain graphies and checking it in gaita. Endoscopic procedures and, if necessary, surgical interventions are recommended when lack of passage is detected in the esophagus for 48 hours and in the stomach and duodenum for 4 days and for objects greater than 5 centimeters (can not pass from the lower esophageal sphincter and pylorus). If the object in the intestinal loops is not pointed, with an interval of 4 days, the object can be followed for 6 weeks. An object that can lead to a chemical reaction must be treated urgently (1, 2, 4-6).

Conclusion

As a result, foreign body ingestion is a condition that can be common in childhood. In 98% of cases without any interference, foreign bodies exact from the gastrointestinal tract freely. Radiology has a big role in the detection and follow-up of the passage of the foreign body. In cases of hesitation, interventional methods should be consulted.

Informed Consent: Written informed consent was not obtained from the patient, because no information or photograph was shared in this paper that could identify the patient.

Peer-review: Externally peer-reviewed.

Author Contributions: Concept - Y.K., D.Ç.O.; Design - E.Ö., R.Ö.; Supervision - D.Ç.O.; Materials - Y.K., R.Ö.; Data Collection and/or Processing - A.İ., İ.İ.; Analysis and/or Interpretation - Y.K., E.Ö.; Literature Review - Y.K.; Writer - Y.K.; Critical Review - D.Ç.O.

Conflict of Interest: The authors declared no conflict of interest.

Financial Disclosure: The authors declared that this study has received no financial support.

References

1. Aydoğdu S, Arikan C, Cakir M, Baran M, Yükksekaya HA, Saz UE, et al. Foreign body ingestion in Turkish children. *Türk J Pediatr* 2009; 51: 127-32.
2. Tiryaki HT, Akbiyik F, Şenel E, Mambet E, Livanelioğlu Z, Atayurt HF. Çocukluk Çağında Yabancı Cisim Yutulması. *Turkish J Pediatr Dis* 2010; 4: 94-9.
3. Deeba S, Purkayastha S, Jeyarajah S, Darzi A. Surgical removal of a tea spoon from the ascending colon, ten years after ingestion: a case report. *Cases J* 2009; 2: 7532. [\[CrossRef\]](#)
4. Liu YC, Zhou SH, Ling L. Value of helical computer tomography in the early diagnosis of esophageal foreign bodies in adults. *Am J Emerg Med* 2013; 31: 1328-32. [\[CrossRef\]](#)
5. Erbil B, Karaca MA, Aslaner MA, Ibrahimov Z, Kunt MM, Akpınar E, et al. Emergency admissions due to swallowed foreign bodies in adults. *World J Gastroenterol* 2013; 19: 6447-52. [\[CrossRef\]](#)
6. Venkataraghavan K, Anantharaj A, Praveen P, Rani SP, Krishnan BM. Accidental ingestion of foreign object: Systematic review, recommendations and report of a case. *Saudi Dent J* 2011; 23: 177-81. [\[CrossRef\]](#)
7. Hazer B, Dandin O, Karakaş DO. A rare cause of acute appendicitis: an ingested foreign body. *Ulus Travma Acil Cerrahi Derg* 2013; 19: 570-2. [\[CrossRef\]](#)