

A Rare Cause of Intraabdominal Haemorrhagy Ethiology: Retroperitoneal Haemorrhagic Cyst

© Mehmet Buğra Bozan¹, © Fatih Mehmet Yazar¹, © Özlem Güler², © Ömer Faruk Boran³, © Ayşe Azak Bozan⁴

¹Department of Surgery, Kahramanmaraş Sütçü İmam University Faculty of Medicine, Kahramanmaraş, Turkey

²Department of Emergency Medicine, Kahramanmaraş Sütçü İmam University Faculty of Medicine, Kahramanmaraş, Turkey

³Department of Anesthesiology and Reanimation, Kahramanmaraş Sütçü İmam University Faculty of Medicine, Kahramanmaraş, Turkey

⁴Department of Anesthesiology and Reanimation, Kahramanmaraş Necip Fazıl State Hospital, Kahramanmaraş, Turkey

Abstract

Primary retroperitoneal cysts are rare benign lesions. Generally, these lesions originates from lymphatic system hipoplasia or pelvic or retroperitoneal operations. Although it is usually asymptomatic, they can cause symptoms as hipotension, tachycardia or even shock due to intracystic haemorrhagy, gas retention or hydronephrosis due to compression of adjacent organs. Definitive diagnosis is difficult before surgery. However, diagnosis can be estimated by direct graphy, computed tomography, ultrasound and other techniques. Conservative treatments, percutaneous drainage, marsupialization, open or laparoscopic cyst excision are the treatment options. In this case report, we present a case of retroperitoneal hemorrhagic cyst which was opened to the abdomen causing acute abdomen.

Keywords: Acute abdomen, retroperitoneal cyst, intraabdominal hemorrhage

Introduction

Retroperitoneal cysts are rare, usually asymptomatic, slow growing, abdominal lesions. Although it is often observed as an asymptomatic mass, it can be seen with symptoms such as cyst exerting pressure on surrounding tissues (such as hydronephrosis, gaseous distension) and intracystic hemorrhage (1,2).

In this case report, we presented the patient who was admitted with acute abdomen due to rupture of intracystic hemorrhage into the abdomen.

Case Report

A 45-year-old woman who had abdominal pain for about two days was admitted to the emergency department. The patient also had complaints of palpitation and fatigue. Physical examination revealed widespread tenderness and rebound in the abdomen. No pathology was found in other system examinations. The patient's hemoglobin level and hematocrit level were 8 gr/L and 23.7%. No other pathological findings were

observed. No pathologies were observed on abdominal X-ray. In emergency abdominal computed tomography (CT), on the left, a lesion with intra-heterogeneous character, approximately 10.5x8.5 cm in size, was observed in retroperitoneal space, and a cystic mass was observed in right ovarian, approximately 4x5 cm in size (Figures 1-3). In the follow-up of the patient who was hospitalized by the obstetrics clinic, tachycardia and hypotension and shock clinic was observed despite blood and fresh frozen plasma. An emergent surgery was performed after observing hypovolemic shock. A single dose of prophylactic cefazolin 1 g was administered intravenously prior to the operation, then the abdomen was entered with pfannenstiel incision. Widespread hemorrhagic fluid was observed in the abdomen. Following the observation that the bleeding was not originated from the ovarian mass, the general surgery department was included to the operation. Abdomen was entered with a midline incision on upper and lower abdomen. In the exploration conducted, intraabdominal hemorrhagic fluid was observed. After aspiration of the fluid, when the exploration continued, a bleeding area of approximately 5 cm from the retroperitoneal area was observed



Corresponding Author: Asst. Prof. Mehmet Buğra Bozan, Ph.D., Department of Surgery, Kahramanmaraş Sütçü İmam University Faculty of Medicine, Kahramanmaraş, Turkey
E-mail: bbozan@yahoo.com ORCID ID: orcid.org/0000-0001-5573-2645

Cite this article as: Bozan MB, Yazar FM, Güler Ö, Boran ÖF, Azak Bozan A. A Rare Cause of Intraabdominal Haemorrhagy Ethiology: Retroperitoneal Haemorrhagic Cyst. Eurasian J Emerg Med. 2022;21(2):152-5.

©Copyright 2022 by the Emergency Medicine Physicians' Association of Turkey
Eurasian Journal of Emergency Medicine published by Galenos Publishing House.

Received: 03.11.2019

Accepted: 13.05.2020

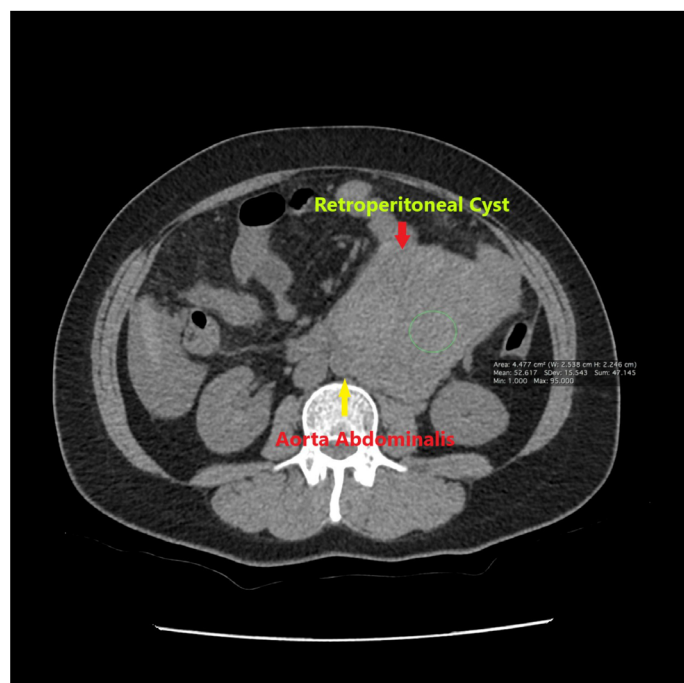


Figure 1. Preoperative coronal computerized tomographic view of the haemorrhagic cyst

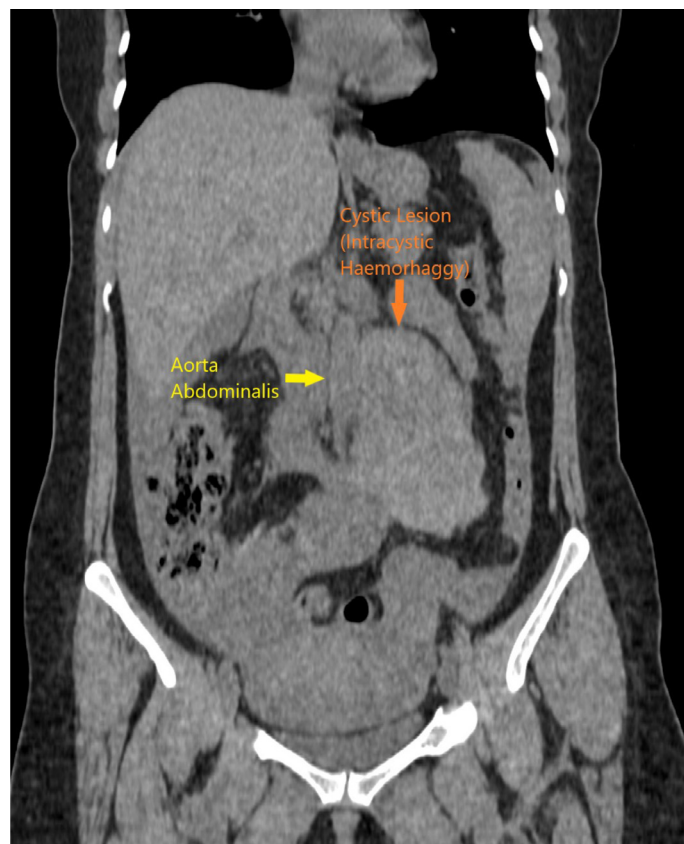


Figure 2. Preoperative sagittal computerized tomographic view of the haemorrhagic cyst

just below the treitz ligament. No aneurysmatic dilatation of aorta was observed. Bleeding was observed in the form of leakage (Figures 4 and 5). Surgicel was applied for homeostasis, and cyst was excised. The operation was terminated. With no complaints and complications in the postoperative period, the patient was discharged.

Discussion

Etiology of nontraumatic retroperitoneal hemorrhages involves an aneurysmatic dilatation of retroperitoneal vessels. Hemorrhages in retroperitoneal vessels without aneurysmatic dilatation are more rare pathologies.

Retroperitoneal cysts are one of the rare pathologies (estimated and expected incidence rates range from 1/5,750 to 1/250,000) (3). As in our case, primary retroperitoneal cystic lesions are benign lesions that do not show any association with other organs or other retroperitoneal structures (1). They are usually formed due to hypoplasia of the congenital lymphatic system, or pelvic or retroperitoneal operations (2). Our case had no known history of pelvic or retroperitoneal operation.

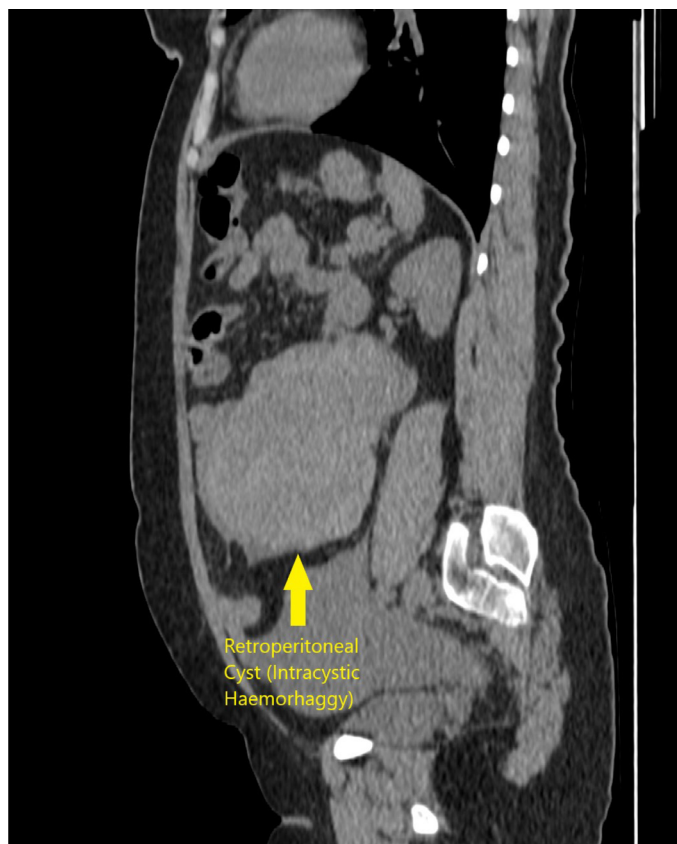


Figure 3. Preoperative axial computerized tomographic view of the haemorrhagic cyst

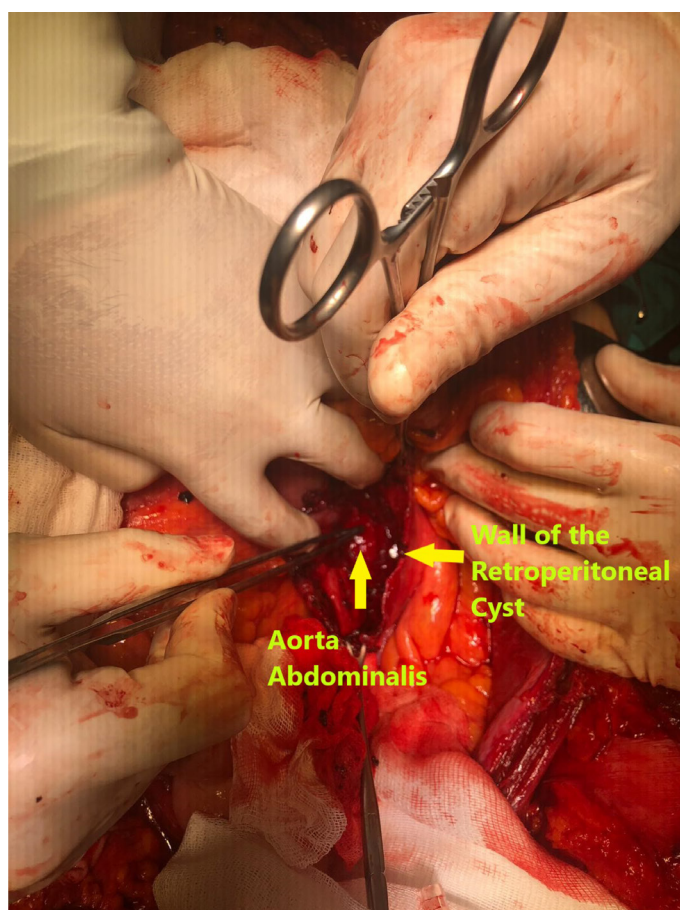


Figure 4. Intraoperative view of the ruptured haemorrhagic cyst

In the early stage, most cysts are asymptomatic; this is due to the anatomically deep and large cavities, because of the anatomic structure of the retroperitoneal space. At the same time, retroperitoneal lymphatic cysts grow slowly and do not show invasion. However, if the cyst grows too large, the infection may cause some symptoms such as intracystic hemorrhage, gaseous distension as a result of pressure exerted on surrounding tissues, and hydronephrosis as in our case (2). In our case, the cyst has bled into itself, and then it was perforated, causing intra-abdominal hemorrhage.

Sometimes painless mass can be palpated in patients (4). It is easily misdiagnosed, and should be distinguished by other intra-abdominal cysts (liver cysts, renal cysts, pancreatic cysts, cystic tumor lesions, cystic teratoma and ovarian cysts as in our case) (5,6). Our patient's initial diagnosis was ovarian cyst, for this reason she was firstly operated by gynecology department. After whole examination and determination of retroperitoneal cyst haemorrhage our General Surgery Department was included into the operation.

Definite preoperative diagnosis is difficult (2). However, it can be estimated by direct radiography, CT, ultrasound and

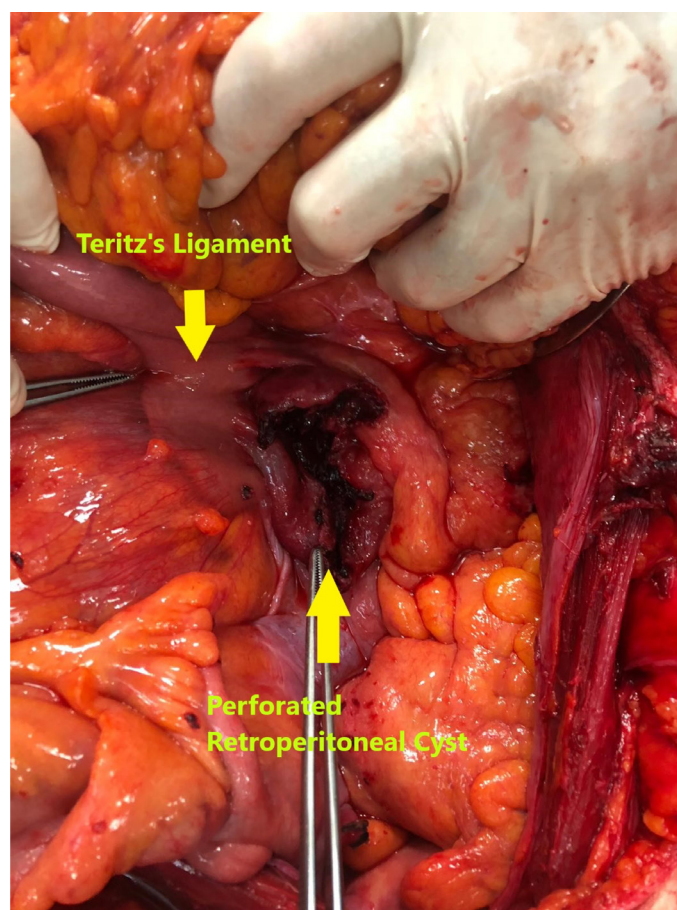


Figure 5. Intraoperative view of the ruptured haemorrhagic cyst

other techniques (2). In our case, a lesion was observed in retroperitoneal space in CT, adjacent to the aorta, filled with hemorrhagic fluid in the cyst.

Narrow and deep retroperitoneal space makes surgery difficult, therefore, open surgery is usually the first choice. However, laparoscopic techniques may also be preferred (7). Our case was operated following hemorrhagic shock, and the patient underwent cystectomy with open surgery. If cyst have pressure symptoms, different techniques such as conservative follow-up, percutaneous catheter drainage with or without sclerotherapy and internal marsupialization can be used (2). However, recurrence rates are 13% in the 6-month follow-up after the first successful drainage (8).

In conclusion, in non-traumatic hemorrhage cases in emergency service applications, gynecological pathologies and aneurysmatic dilatations of vascular structures are common pathologies. However, secondary hemorrhage to retroperitoneal cyst hemorrhage, which is a rare cause, should also be considered among etiologic factors.

Ethics

Informed Consent: It was obtained.

Peer-review: Externally peer-reviewed.

Authorship Contributions

Surgical and Medical Practices: M.B.B., F.M.Y., Ö.G., Ö.F.B., A.A.B., Concept: M.B.B., F.M.Y., A.A.B., Design: M.B.B., Ö.G., Ö.A.B., Data Collection or Processing: M.B.B., A.A.B., Analysis or Interpretation: F.M.Y., Ö.G., Ö.F.B., Literature Search: M.B.B., Ö.F.B., A.A.B., Writing: M.B.B., F.M.Y., A.A.B.

Conflict of Interest: No conflict of interest was declared by the authors.

Financial Disclosure: The authors declared that this study received no financial support.

References

1. Jha AK, Shrestha S, Sharma S. Idiopathic retroperitoneal cyst in an adult male. *Urol Ann.* 2017;9:272-4.
2. Wang Y, Chen C, Zhang C, Qin C, Song N. Extraperitoneal laparoscopic resection for retroperitoneal lymphatic cysts: initial experience. *BMC Urol.* 2017;17:101.
3. Guile M, Fagan M, Simopolous A, Ellerkmann M. Retroperitoneal cyst of mullerian origin: A case report and review of literature. *J Pelvic Med Surg.* 2007;13:149-52.
4. Martin-Perez E, Tejedor D, Brime R, Larranaga E. Cystic lymphangioma of the lesser omentum in an adult. *Am J Surg.* 2010;199:e20-2.
5. Dong B, Zhou H, Zhang J, Wang Y, Fu Y. Diagnosis and treatment of retroperitoneal bronchogenic cysts: a case report. *Oncol Lett.* 2014;7:2157-9.
6. Thaler M, Achatz W, Liebensteiner M, Nehoda H, Bach CM. Retroperitoneal lymphatic cyst formation after anterior lumbar interbody fusion: a report of 3 cases. *J Spinal Disord Tech.* 2010;23:146-50.
7. Ahn KS, Han HS, Yoon YS, Kim HH, Lee TS, Kang SB, et al. Laparoscopic resection of nonadrenal retroperitoneal tumors. *Arch Surg.* 2011;146:162-7.
8. Kim JK, Jeong YY, Kim YH, Kim YC, Kang HK, Choi HS. Postoperative pelvic lymphocele: treatment with simple percutaneous catheter drainage. *Radiology.* 1999;212:390-4.